

## Mad-Honey intoxication leading to severe arrhythmia

### *Ciddi aritmiye yol aan Deli-Balı zehirlenmesi*

Davut Baltacı<sup>1</sup>, Serkan Öztürk<sup>2</sup>, Kayıhan Karaman<sup>3</sup>, Hayati Kandıř<sup>4</sup>, Ayhan Sarıtař<sup>5</sup>

<sup>1</sup>Düzce Üniversitesi Tıp Fakültesi Aile Hekimliği Anabilim Dalı, Düzce, Türkiye

<sup>2</sup>Abant İzzet Baysal Üniversitesi, Tıp Fakültesi, Kardiyoloji Anabilim Dalı, Bolu, Türkiye

<sup>3</sup>Kahramanmarař Devlet Hastanesi, Kardiyoloji Kliniđi, Kahramanmarař, Türkiye

<sup>4,5</sup>Düzce Üniversitesi Tıp Fakültesi, Acil Anabilim Dalı, Düzce, Türkiye

#### ABSTRACT

Mad honey intoxication is rarely and locally seen, and it can cause cardiac arrhythmias from mild to life threatening health problems. A 52 year-old female patient admitted to our emergency room with dizziness and fatigue after ingestion of bitter honey. On examination in emergency room, her blood pressure was 70/40 mmHg and pulse value was 45/min. Atrial fibrillation and AV complete block rhythm was detected on her Electrocardiography (ECG) recording. She had no history of known-cardiac disease and use of medicine. On follow-up, her general health status got back to normal. The patient was discharged after her medical status was improved. In conclusion bitter honey intoxication can be life-threatening arrhythmias in people after ingestion of it. It is not restricted health problem to only that region of Turkey, but also to worldwide due to increase in people movement and international nutrition transport. *J Clin Exp Invest* 2011;2(2):216-8

**Key words:** Mad-honey, intoxication, arrhythmias, grayanotoxin.

#### INTRODUCTION

Mad-honey is named as a jar of honey which is produced by bees from the nectar of a kind of plant species containing grayanotoxin. Grayanotoxin is extracted by bees from the leaves and flowers of those plants species, and is the main compounds responsible for this poisoning. Dizziness and perspiration, vomiting and syncope are typical symptoms seen after 30-60 minutes after ingestion of honey containing grayanotoxin, and commonly observed in almost all cases.<sup>1</sup> On physical examination, hypotension, bradycardia and cardiac conduction defect was detected in patients admitted to health centers. These conduction defects cover AV complete

#### ÖZET

Deli balı zehirlenmesi nadir ve yerel görülen hafif düzeyden ciddi hayatı tehdit eden kardiyak aritmilere neden olabilmektedir. Olgumuz 52 yařında bayan bir hasta deli balı alımı sonrası, yorgunluk, sersemlik ve bař dönmesi řikayeti ile acil servisimize bařvurdu. Yapılan fizik muayenesinde tansiyonu 70/40 mmHg, nabızı 45/dk idi. Öncesinde kardiyak hastalıđı ve ilaç kullanımı olmayan hastanın elektrokardiografi (EKG) kaydında atriyal fibrilasyon ve atriyoventriküler (AV) tam blok gözlemlendi. Hasta acil müdahale sonrası takibe alındı. Takiplerinde řikayetleri gerileyen ve genel durumu stabil olan hasta öneriler ile taburcu edildi. Sonuç olarak, deli balı alımı sonrası hayatı tehdit eden aritmiler oluşabilmektedir. Bu sađlık problemi sadece Türkiye’de bazı bölgelerle sınırlı değildir, besin taşıyıcılıđı ile bütün dünyada artış göstermektedir. *Klin Deney Ar Derg* 2011;2(2):216-8

**Anahtar kelimeler:** Deli balı, zehirlenme, aritmiler, grayanotoksin.

block, second-degree heart block, nodal rhythm and asystole.<sup>1,2</sup>

An unusual type of food poisoning, commonly seen in the eastern Black Sea region in Turkey, is caused by toxic honey. The honey is well known and is named ‘mad honey’ by local people living in this area. Almost all case reported in literatures are from area covering *Rhododendron* familia vegetation found on mountainous region of this area.<sup>2</sup>

Sometimes, mad-honey intoxication can cause cardiac problems on changing level from mild to severe life-threatening hemodynamic results. Therefore, here, we presented a case of mad-honey intoxication admitted to our health center, and we

**Yazıřma Adresi /Correspondence:** Dr. Davut Baltacı,

Düzce Üniversitesi Tıp Fakültesi Aile Hekimliği Anabilim Dalı, Düzce, Türkiye Email: davutbaltaci@hotmail.com

Geliř Tarihi / Received: 20.12.2010, Kabul Tarihi / Accepted: 09.04.2011

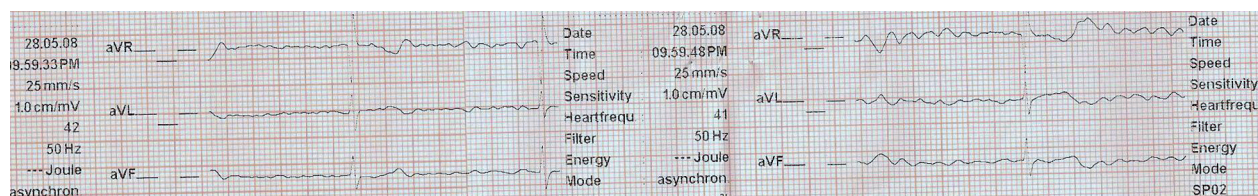
Copyright © Klinik ve Deneysel Arařtırmalar Dergisi 2011, Her hakkı saklıdır / All rights reserved

review management of the patients with this type of intoxication.

## CASE

A 52 year-old female patient admitted to our emergency room with dizziness and fatigue after having some amount of honey produced in Surmene plateaus. On examination, her blood pressure pulse was 70/40 mmHg and 45/min respectively. Atrial fibril-

lation and AV complete block rhythm was detected on her ECG recording (Figure 1). Without delay, 1 mg IV atropine was administered to patient, then her pulse value was 60/min up and 90/70 mmHg of blood pressure was measured. She had no history of known-cardiac disease and medical use. On follow-up, her general health status improved. The patient was discharged after observing normal sinus rhythm on ECG recording on second day of admission.



**Figure 1.** Atrial fibrillation and AV complete block due to mad-honey intoxication.

## DISCUSSION

The patients with mad-honey intoxication admit to emergency room with heart symptoms. As have been reported in almost all of cases of mad-honey poisoning, it is associated with effect on heart disorders. In recent reports, atrio-ventricular block (AV) types which are triggered by mad-honey poisoning have been reported. Although complete AV blocks are common, primary-degree AV blocks are also in recent cases.<sup>3,4</sup> The most common arrhythmias were sinus bradycardia and nodal rhythm reported in past case series. However, number of different cases due to grayanotoxin intoxication increases recent days. In more than 70% of 14 case series reported in literatures, non-specific bradyarrhythmia and sinus bradycardia were reported. Heart block disorders accounts for more than 25% of these cases, and asystole was reported in one case.<sup>5</sup>

Grayanotoxin is a toxin which is found in honey made from rhododendrons nectar. It binds to specific sodium ion channels in cell membrane. Symptoms due to grayanotoxin are dose-dependent latent period of minutes to hours or so. Significant hypotension and bradycardia are common symptoms after intoxication. Besides these symptoms, dizziness, perspiration, syncope and altered mental status can be also commonly seen. Diplopia and blurred vision are also reported in cases, but salivation is seldom.<sup>6,8</sup> Despite the potential cardiac problems, the condi-

tions are rarely fatal and generally lasts less than a day. Medical interventions are not often needed but sometimes atropine therapy, vasopressin is used to.<sup>9</sup> It generally responds to IV atropine administration. Health status of patients with mad honey intoxication usually improves with IV atropine administration and enough hydration. The patients not responding to this treatment may require bradycardia algorithm declared in Guidelines of High Cardiac Life Support.<sup>1</sup>

When we consider distribution of Rhododendron plant species on the world, it can be potentially seen all over the world, so we can face similar cases. We emphasize that it is not only seen in sea coast long of black sea region of Turkey, but also can be seen in all over the world. It is not restricted health problem to only that region of Turkey due to increase in people movement and international nutrition transport.

In conclusion, on based our recent knowledge about mad-honey intoxication, physicians should be aware of that this intoxication can be life threatening arrhythmias in people taking it. Physician working in primary care health services should be clinically updated about management of mad-honey intoxication Today's, we have still insufficient experience and data about mad-honey intoxication, so further pharmacological investigations should be done.

**REFERENCES**

1. Gunduz A, Turedi S, Russell RM, Ayaz FA. Clinical review of grayanotoxin/mad honey poisoning past and present. *Clin Toxicol (Phila)*. 2008; 46(5):437-42.
2. Gunduz A, Bostan H, Turedi S, et al. Wild flowers and mad honey. *Wilderness Environ Med*. 2007; 18(1):69-71.
3. Weiss TW, Smetana P, Number M. The honey man--second degree heart block after honey intoxication. *Int J Cardiol*. 2010 25; 142(1):e6-7.
4. Yilmaz O, Eser M, Sahiner A, et al. Hypotension, bradycardia and syncope caused by honey poisoning. *Resuscitation*. 2006; 68(3):405-8.
5. Ozhan H, Akdemir R, Yazici M, et al. Cardiac emergencies caused by honey ingestion: a single centre experience. *Emerg Med J*. 2004; 21(6):742-4.
6. Dursunoglu D, Gur S, Semiz E. A case with complete atrio-ventricular block related to mad honey intoxication. *Ann Emerg Med*. 2007; 50(4):484-5.
7. Gunduz A, Durmus I, Turedi S, Nuhoglu I, Ozturk S. Mad honey poisoning-related asystole. *Emerg Med J*. 2007;24(8):592-3.
8. Choo YK, Kang HY, Lim SH. Cardiac problems in mad-honey intoxication. *Circ J*. 2008; 72(7):1210-1.
9. Yildirim N, Aydin M, Cam F, Celik O. Clinical presentation of non-ST-segment elevation myocardial infarction in the course of intoxication with mad honey. *Am J Emerg Med*. 2008; 26(1):108.e1-2.