

Erratum Notice for Immunohistochemical Localization of Androgen Receptor in Rat Caput Epididymis during Postnatal Development

Fatih Mehmet Gür¹, Sema Timurkaan²

¹ Sabiha Gökçe International Airport
Veterinary Border Inspection
Directorate, Istanbul, Turkey

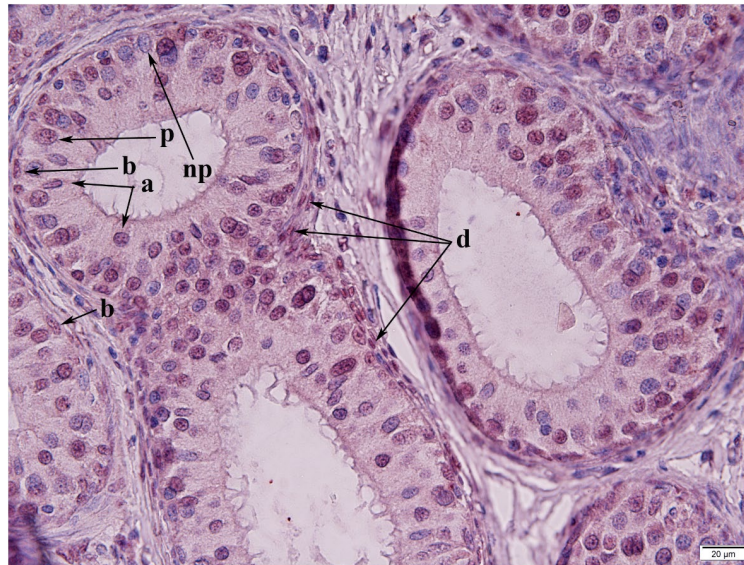
² Firat University, Faculty of
Veterinary Medicine, Department of
Histology and Embryology, Elazig,
Turkey

ORIGINAL ARTICLE

Gür FM, Timurkaan S. Immunohistochemical localization of androgen receptor in rat caput epididymis during postnatal development. J Clin Exp Invest. 2011;2(3):260-6.

<https://doi.org/10.5799/ahinjs.01.2011.03.0051>

This document states that “Şekil 2” in the original article should be replaced as follows:



Şekil 2. 56 günlük sıçanlarda kaput epididimal hücrelerdeki AR lokalizasyonu. a, apikal hücre; b, bazal hücre; p, esas hücre; np, negatif esas hücre; d, peritubuler düz kas hücresi.

Correspondence:

Sema Timurkaan

Address: Firat University, Faculty of
Veterinary Medicine, Department of
Histology and Embryology, Elazig,
Turkey

Email: stimurkaan@hotmail.com

Received: 09.10.2019,

Accepted: 10.10.2019

<https://doi.org/10.5799/jcei/5956>